Fibrosing Interstitial Lung Disease

A Practical High-Resolution Computed Tomography–based Approach to Diagnosis and Management and a Review of the Literature

Philip A. Hodnett[1]* and David P. Naidich[1]

[1]Thoracic Imaging Section, Department of Radiology, New York University Langone Medical Center, Center for Biological Imaging, New York, New York

Establishing the etiology of fibrosing interstitial lung disease (FILD) remains a clinical challenge. This is because many disorders resulting in lung fibrosis may be similar in their initial clinical and radiographic appearances. High-resolution computed tomography (HRCT) studies are now almost always obtained for patients who present with otherwise nonspecific clinical symptoms and chest radiographic findings. In the majority of cases presenting with FILD, differential diagnosis typically requires differentiating among three most commonly encountered clinical entities: idiopathic pulmonary fibrosis with usual interstitial pneumonia, nonspecific interstitial pneumonia, and chronic hypersensitivity pneumonitis. As a consequence, the development of a simplified diagnostic algorithmic approach initially focusing on the interpretation of HRCT findings may prove of considerable value provided thorough familiarity with optimal HRCT techniques and methods of interpretation. For this purpose, in patients with FILD in whom an underlying etiology is not initially apparent, the recently proposed American Thoracic Society/European Respiratory Society/Japanese Respiratory Society/Latin American Thoracic Association guidelines for the diagnosis of IPF have been modified to create a straightforward, clinically practicable algorithmic approach to clinical management based on the initial interpretation and classification of HRCT findings.

Keywords: fibrosing interstitial lung disease; usual interstitial pneumonia; nonspecific interstitial pneumonia; chronic hypersensitivity pneumonitis; connective tissue disease

Traditional classifications of interstitial lung diseases have primarily focused on known underlying associations, including connective tissue diseases (CTD), granulomatous diseases, environmental etiologies, drug-induced causes, smoking-related disorders, and vasculitides (1). In addition, there are idiopathic forms of interstitial lung disease (2). These diseases have different histopathologies, many of which can result in fibrosing interstitial lung disease (FILD) and frequently lack characteristic history or physiologic alterations at the time of presentation. Despite the large number of conditions associated with FILD, in fact only a few are commonly encountered in routine clinical practice (1). These include entities that may be associated with known underlying etiologies that are nonetheless undiagnosed at presentation. These most importantly include idiopathic pulmonary fibrosis (IPF) with usual interstitial pneumonia (UIP), nonspecific interstitial pneumonia (NSIP), and chronic hypersensitivity pneumonitis (HP). Developing a simplified approach to diagnosis in the absence of a known underlying etiology initially focusing on high-resolution computed tomography (HRCT) interpretation, therefore, is a priority. To date, only a few previous reports have emphasized the need to consider an alternate approach (3, 4).

The purpose of this review is therefore to present a simplified and practical clinical–algorithmic approach to the diagnosis of patients initially presenting with FILD in the absence of a known underlying etiology (5). Those HRCT features that allow diagnostic distinctions will be reviewed, with emphasis placed on implications of HRCT findings both for prognosis as well as for clinical management. For this purpose, optimal HRCT techniques and criteria of interpretation will first be presented, with particular emphasis on current HRCT definitions of honeycombing. After this, HRCT findings of those few diseases most commonly presenting with lung fibrosis will be briefly reviewed, with emphasis on identifying features of greatest value in differential diagnosis and subsequent management.

HRCT: TECHNIQUE

There are two general approaches to performing an HRCT examination. The traditional method involves obtaining spaced axial/cross-sectional images effectively sampling the lung, typically at 1- to 2-cm intervals. Alternatively, with the advent of multidetector computed tomography (MDCT) scanners, it is now possible to scan the entire thorax in a single breathhold, allowing reconstruction of contiguous high-resolution images. Conventional spaced HRCT protocols have several inherent limitations, most importantly nonvisualization of small focal abnormalities between slices and a greater likelihood of breathing artifacts (6, 7). In contrast, MDCT allows acquisition of high-resolution contiguous slices simultaneously allowing close tracking of subtle parenchymal and airway abnormalities on sequential adjacent sections. MDCT also enables routine reconstruction of high-quality isotropic multiplanar coronal reformats without the need to obtain additional scans, limiting radiation exposure. Consequently, coronal multiplanar coronal reformats in particular should be obtained in all computed tomography (CT) studies. Unless contraindicated, all scans should be obtained with a low-dose technique. Although the definition of a low-dose study is still evolving, acceptable images can be obtained in all but the most obese patients using 80 mA. Use of lower dose using standard reconstruction methodology can adversely affect image interpretation. In a recent study assessing the accuracy of standard versus low-dose (40 mA) CT scan to evaluate diffuse interstitial disease, detection decreased from 91

(*Received in original form August 27, 2012; accepted in final form May 2, 2013*)

* Present address: Department of Radiology, University Hospital, Limerick, Dooradoyle, Limerick, Ireland.

Correspondence and requests for reprints should be addressed to David P. Naidich, M.D., Division of Thoracic Imaging, NYU-Langone Medical Center, Center for Biological Imaging, 660 First Avenue, New York, NY 10016. E-mail: david.naidich@nyumc.org

CME will be available for this article at http://ajrccm.atsjournals.org or at http://cme.atsjournals.org

Am J Respir Crit Care Med Vol 188, Iss. 2, pp 141–149, Jul 15, 2013
Copyright © 2013 by the American Thoracic Society
Originally Published in Press as DOI: 10.1164/rccm.201208-1544CI on May 14, 2013
Internet address: www.atsjournals.org

to 71% ($P < 0.0001$) (8). However, it should be emphasized that currently commercial available techniques lead to marked reductions in radiation dose compared with routine CT scanning. These include, among others: automatic tube current (mA) modulation; optimization of tube potential; beam-shaping filters; dynamic z-axis collimators; and, in particular, iterative reconstruction techniques. All these techniques are available on current state-of-the-art CT scanners, and their use should be considered when available. Of particular interest is the use of iterative reconstruction techniques, which allows nearly 50% dose reduction without sacrificing image quality (9).

Given these advantages, multidetector volumetric CT acquisition is now the preferred method, especially for initial CT examinations, because of improved identification of frequently characteristic localized manifestations of diffuse disease and identification of otherwise potentially overlooked ancillary findings (10). In contrast, spaced axial imaging may still be of value whenever numerous follow-up HRCT studies prove necessary, as occurs, for example, in younger individuals with chronic granulomatous diseases. Finally, in the assessment of patients with known or suspected diffuse lung fibrosis, a few low-density spaced expiratory images should also be acquired routinely in all patients. As will be discussed, identification of secondary lobular air trapping may be of critical diagnostic value for differentiating chronic HP from UIP and NSIP (11).

HRCT INTERPRETATION

To provide a systematic approach to the interpretation of HRCT images, various attempts have been made to standardize terminology, most recently by the Fleischner Society (12). Central to the interpretation of FILD is identification of the extent, distribution, and severity of the following findings: parenchymal reticulation, centrilobular nodules, foci of low attenuation with or without definable walls, ground-glass attenuation, traction bronchiectasis and bronchiolectasis, regional air trapping, architectural distortion, and honeycombing. Although there is general consensus regarding the definition of these signs, controversy regarding the pathologic and especially the HRCT definition of honeycombing remains especially problematic (13–15).

Honeycomb Lung

As recently reviewed by Arakawa and Honma, histopathologic and radiographic definitions of honeycombing have changed over time (16). The final common feature of end-stage FILD, regardless of the etiology, is honeycombing. Histopathologically, this has been defined as cystic dilatation of terminal and respiratory bronchioles consequent to fibrotic destruction of adjacent airspaces. Put forth by Katzenstein (17), honeycombing represents the nonspecific result of a number of diseases, including but not restricted to the idiopathic interstitial pneumonias. It is depicted by "relatively uniformly sized cysts characterized by enlarged airspaces surrounded by fibrosis and lined by bronchiolar or hyperplastic alveolar epithelium," with collapse and collagen deposition the major underlying cause of the gross and microscopic appearances.

As defined by the 2008 Fleischner Society statement (12), and based on HRCT imaging, honeycombing represents "clustered cystic air spaces, typically of comparable diameters on the order of 3–10 mm but occasionally as large as 2.5 cm," typically with a subpleural location. They are characterized by definable walls, with cysts typically lined up adjacent to one another. Importantly, this characterization specifically excludes traction bronchiolectasis as a defining feature of honeycombing. This is important, given that honeycombing as defined by HRCT is now considered the key diagnostic feature for establishing a diagnosis of UIP (Figure 1) (12, 18).

Given the critical importance of establishing the presence of honeycombing, limitations in the diagnosis have been documented. As documented by Watadani and colleagues, patterns of findings that may cause particular diagnostic difficulty include

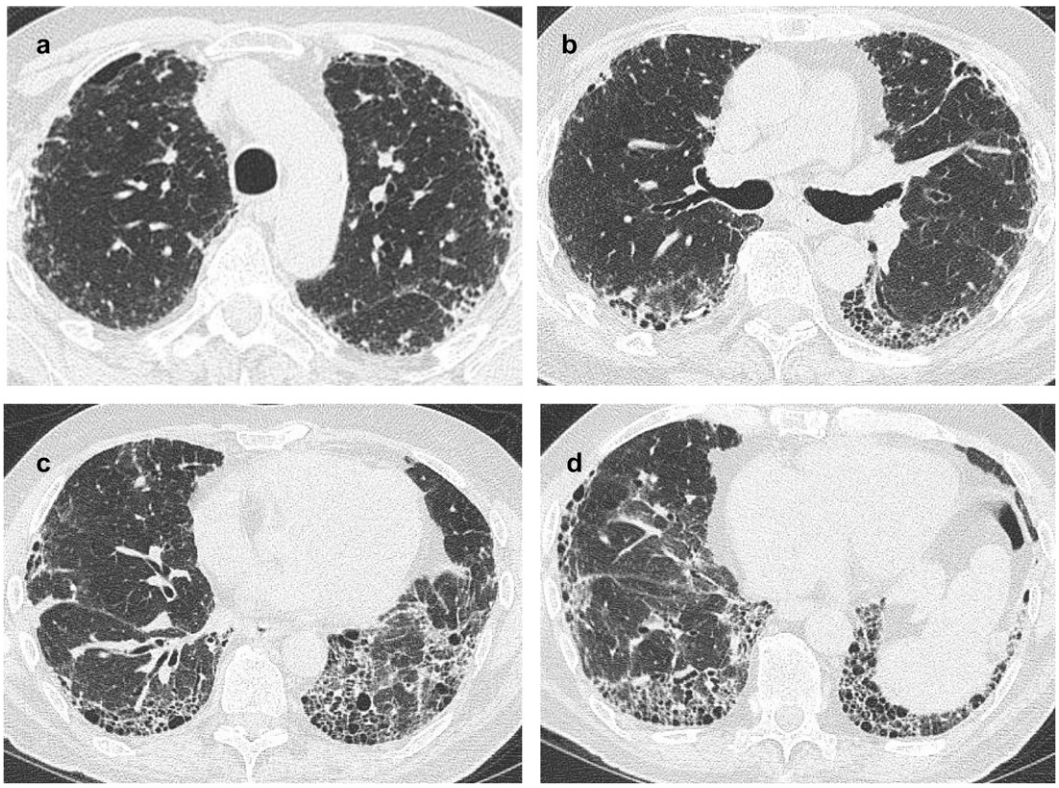

Figure 1. Usual interstitial pneumonia (UIP) pattern. (*a–d*) Sequential high-resolution computed tomography images through the lung demonstrate a classic UIP pattern with evidence of diffuse reticulation, traction bronchiectasis, and subpleural, basilar honeycombing. In the absence of a known underlying etiology, this appearance is diagnostic of idiopathic pulmonary fibrosis, for which surgical biopsy is not indicated.

typical honeycombing that is limited in extent, with or without clustered cysts, when either subpleural and/or peribronchial in distribution (Figures 1–4) (15). Problems also may arise when differentiating subtle honeycombing from paraseptal emphysema, which often occurs in conjunction with UIP (16). The finding of a single basilar layer of apparent cysts is considered by some as consistent with honeycombing and hence pathognomic for IPF; however, the finding of multiple layers of variable-sized subpleural cysts with definable walls is more definitive. The finding of a single layer of subpleural cysts, especially when thin-walled, should be interpreted with a lower level of confidence with longitudinal evaluation required to increase confidence in the diagnosis of honeycombing (15).

Regardless of the explanation, what is not in dispute is that as a marker for end-stage lung fibrosis honeycombing has profound prognostic implications with relentless disease progression occurring in the majority of cases (19, 20). In these cases, death frequently results from the rapid development of diffuse alveolar damage or supervening pulmonary hypertension. Akira and colleagues, as early as 1993, reported that of 29 patients with documented IPF and honeycombing, 26 showed progression on follow-up CT examinations, with no differences identified between treated versus untreated patients (21).

IPF: THE AMERICAN THORACIC SOCIETY/EUROPEAN RESPIRATORY SOCIETY/JAPANESE RESPIRATORY SOCIETY/LATIN AMERICAN THORACIC ASSOCIATION GUIDELINES

Acknowledging the critical role of HRCT in the diagnosis and subsequent management of patients with IPF, interpretative guidelines have been recently proposed (5). These guidelines require the identification of a "UIP pattern" that in the absence of known causes of interstitial fibrosis enables a definitive diagnosis of IPF without the need to obtain a surgical lung biopsy. As proposed, a UIP pattern requires meeting the following four criteria: that the disease is predominantly subpleural and basilar in distribution, reticular in appearance, and associated with honeycombing in the absence of inconsistent features that suggest an alternate diagnosis. In contrast, a possible UIP pattern is defined as identical to the above criteria with the critical omission of honeycombing. Finally, a third category is defined by the presence of features inconsistent with both a UIP pattern and possible UIP pattern, including any of the following: upper, midlung, or peribronchovascular distribution; extensive ground-glass attenuation, especially if more extensive than reticulation; the presence of profuse micronodules, especially if bilateral and predominantly upper lobe in distribution; discrete cysts distinct from honeycombing; mosaic attenuation, especially due to air trapping involving more than three lobes; and, finally, the presence of segmental or lobar consolidation (5). These inconsistent features suggest alternative causes than IPF. Although proposed as criteria for establishing a definitive diagnosis of IPF, these categories, with important modifications, serve equally well for developing a simplified three-step algorithmic approach to diseases causing FILDs, allowing emphasis to be placed on the few entities most likely to be encountered in routine clinical practice. In particular, this approach specifically emphasizes chronic HP as a major consideration in the differential diagnosis.

FILD: AN INTEGRATED HRCT-BASED MULTIDISCIPLINARY ALGORITHMIC APPROACH

Step 1: Findings Suggest a Definite UIP Pattern

A UIP pattern in the proper clinical setting that includes honeycombing is now considered pathognomonic of IPF, for which a surgical lung biopsy is now no longer indicated (Figure 1). Known causes of a UIP pattern include: drug-induced lung injury, occupational exposure, hypersensitivity pneumonitis, or underlying CTDs. In a recent metaanalysis, a significant increased risk for "IPF" associated with cigarette smoking and exposures to agriculture and farming, livestock, wood and metal dust, stone, and silica have also been noted (22). A UIP pattern can be present in patients with asbestosis. In this case, pleural plaques and/or calcifications may also be present (23, 24). UIP due to a known cause may have a different prognosis and treatment response when compared with IPF (25).

As previously noted, the characteristic HRCT features of a UIP pattern are subpleural reticular opacities/reticulation and macrocystic honeycombing combined with traction bronchiectasis (Figure 1) (26). Although foci of ground-glass attenuation are common, these are typically insignificant when compared with the extent of reticulation and architectural distortion and histologically correspond to micro-honeycombing (27). When present and extensive, consideration should be given to the possible superimposed development of diffuse alveolar damage or infection. The distribution of UIP on HRCT is characteristically basal and peripheral; however, an apicobasal gradient may be present (28).

There is generally good interobserver agreement for the HRCT diagnosis of IPF (29–31). In 2001, Hunninghake and colleagues demonstrated the positive predictive value of a confident diagnosis of IPF was 96% when cases were reviewed by core radiologists (32). In a group of 84 patients diagnosed with IPF by community radiologists, there was 90% agreement with expert thoracic radiologists (13), although community radiologists were less likely to recognize honeycombing (33). Similar results have been reported by Lynch, who reported that of 315 patients with documented IPF of varying severity, there was good correlation between the interpretations of "core" study radiologists and "study-site" radiologists (34). As reported by Flaherty and colleagues in a study evaluating HRCT findings in 96 patients with documented UIP ($n = 73$) and NSIP ($n = 23$), all 27 patients with definite or probable UIP on HRCT had histological UIP (35). As noted in one recent report, when interobserver variability is present, this most often occurs due to the finding of honeycombing in association with traction bronchiectasis, large cysts, and/or superimposed pulmonary emphysema (15).

Step 2: Findings Suggest a Possible UIP Pattern

When findings are suggestive of a possible UIP pattern, differential diagnosis is less specific (Figures 2 and 3). In this setting the clinical problem most frequently encountered is distinguishing UIP from its common potential mimic, NSIP.

Numerous reports suggest that differentiation between UIP and cellular NSIP is often possible. The most frequent feature of cellular NSIP is patchy ground-glass attenuation combined with generally subtle symmetric irregular peripheral and/or subpleural linear or reticular opacities (36, 37). Importantly, in about one-third of cases there is relative sparing of the immediate basilar subpleural lung, along with a peribronchovascular distribution (36, 38, 39). In contrast, in patients with fibrotic NSIP, traction bronchiectasis and bronchiolectasis predominate, albeit often appearing in areas of ground-glass attenuation with varying frequency (27, 40). Actual honeycombing, although atypical, is reported in a minority of patients and is frequently characterized as representing microcystic honeycombing as opposed to the macrocystic honeycombing seen in UIP (41, 42). Although studies have shown that NSIP subtypes can often be distinguished on HRCT by the relative extent of ground-glass attenuation and intralobular reticular opacities,

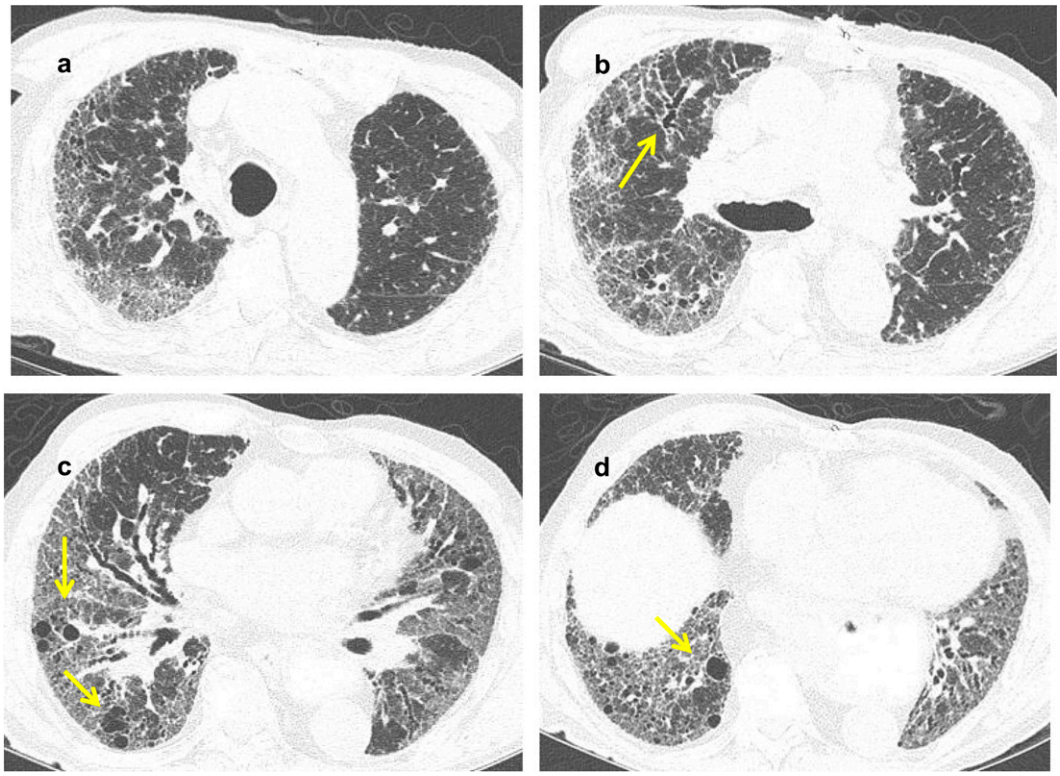

Figure 2. Possible usual interstitial pneumonia pattern. (*a–d*) Sequential high-resolution computed tomography images throughout the lung show extensive subpleural reticulation, traction bronchiectasis (*arrow* in *b*), and ground-glass attenuation. There are several discrete thin-walled cysts identified in the lower lobes (*arrows* in *c* and *d*), which superficially mimic honeycombing. In this case, absence of true honeycombing is an indication for performing surgical lung biopsy.

Johkoh and colleagues (37) have demonstrated that the extent of traction bronchiectasis and intralobular reticular opacities on thin-section CT scan correlates with increased fibrosis (100 vs. 90% and 100 vs. 35%, respectively), further complicating differentiation of UIP from NSIP. Importantly, although most serial HRCT scans initially may demonstrate features characteristic of cellular NSIP, in at least one report, approximately one-third of these cases show fibrotic progression with transition from apparent cellular NSIP to a classic UIP pattern (43).

The difficulty of distinguishing NSIP from UIP has been reported by others (35, 44). In the study by Flaherty and colleagues evaluating 96 patients with either documented UIP or NSIP,

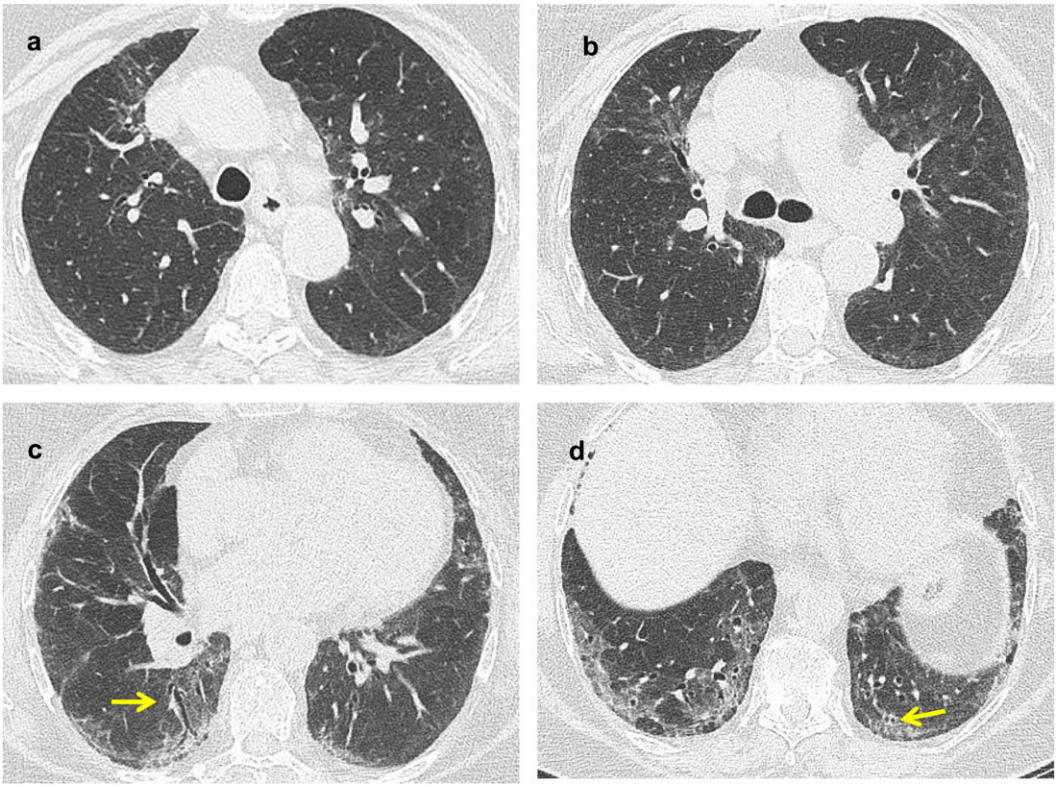

Figure 3. Possible usual interstitial pneumonia (UIP) pattern. (*a–d*) Sequential high-resolution computed tomography images through the lungs also show a possible UIP pattern. In this case, in addition to subpleural reticulation and traction bronchiectasis (*arrows* in *c* and *d*) there is also evidence of subpleural ground-glass attenuation in the same areas of increased reticulation. Again, in the absence of a known etiology, this pattern also requires open lung biopsy confirmation. Biopsy confirmed UIP.

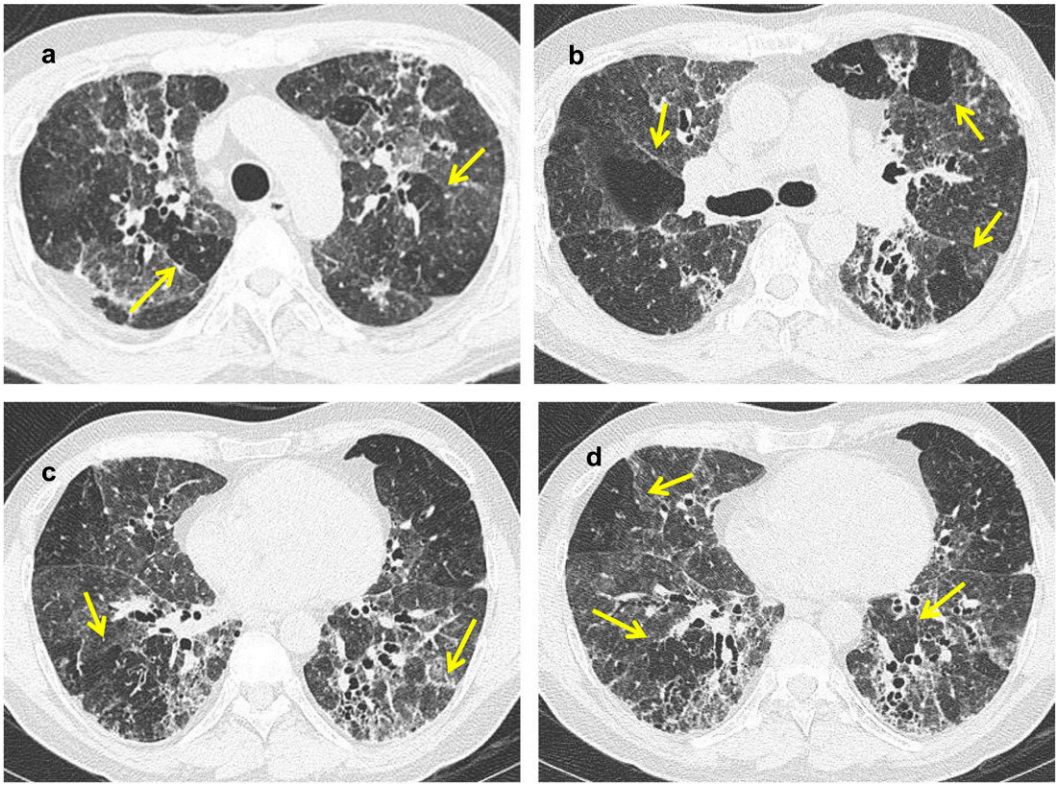

Figure 4. Findings inconsistent with a usual interstitial pneumonia pattern—chronic hypersensitivity pneumonitis. (*a–d*) Sequential high-resolution computed tomography images obtained in inspiration through the lungs. In this case, in addition to diffuse reticulation and traction bronchiectasis, there is also evidence of numerous foci of decreased lung attenuation and vascularity, many with a distinct lobular pattern (*arrows* in *a–d*) strongly suggestive of the diagnosis of chronic hypersensitivity pneumonitis, a diagnosis later confirmed by obtaining a detailed clinical history revealing prolonged use of a hot tub. In the absence of a convincing clinical history, confirmation of this diagnosis may be obtained by bronchoalveolar lavage.

when a definite or probable HRCT diagnosis of UIP was made, there was 100% correlation with the histologic diagnosis (35). In contrast, however, these same investigators noted that in the absence of a UIP pattern, of 25 cases interpreted as indeterminate, 20 proved to be UIP. Of the 25 cases believed to represent fibrotic NSIP, 17 proved to be UIP based on histology, whereas only 8 proved to be NSIP (35). Similarly, McDonald and colleagues found that 33% of subjects with histologic fibrotic NSIP were falsely diagnosed with UIP based on HRCT findings, and 38% of subjects with histologic UIP had HRCT patterns consistent with NSIP (40). Differentiation is complicated by the fact that nearly 30% of patients with documented UIP fail to show evidence of honeycombing (Figure 3). In one recent report in which three observers evaluated HRCT findings in 55 biopsy-proven cases of IPF, alternative diagnoses were considered in 34 (62%) (44). In addition to overlap in the HRCT appearances of UIP/IPF and NSIP, it is also noted that differences in interpretation also reflect variations in interpretive skill. Although interobserver variability is generally acceptable in the diagnosis of diffuse lung fibrosis due to UIP in regional teaching centers, cases diagnosed with low confidence, particularly where NSIP is considered, may benefit from the expertise of a reference panel (33). Finally, agreement on honeycombing depends on the prevalence of other fibrotic features and emphysema that may mimic honeycombing in the study population (45). Despite concerns regarding potential complications, as will be discussed, given the lack of histologic specificity of a possible UIP pattern, consideration should be given to obtaining surgical lung biopsies in these cases.

Step 3: Findings Are Inconsistent with a UIP Pattern

As emphasized by the American Thoracic Society/European Respiratory Society/Japanese Respiratory Society/Latin American Thoracic Association statement regarding the diagnosis of IPF, there is a large category of HRCT appearances that are defined as "inconsistent with a UIP pattern" (5). These include upper, midlung, or peribronchovascular distribution; extensive ground-glass attenuation, especially if greater than the extent of reticulation; diffuse lung nodules, especially if upper lobe, bilateral, and poorly defined "ground-glass" in appearance; discrete cysts; parenchymal consolidation; and air trapping involving more than three lobes. Importantly, left out of this list is the finding of secondary lobular air trapping, a sign best seen on expiratory high-resolution images (5).

Although these findings suggest a wide range of differential diagnoses, including atypical manifestations of UIP and NSIP, the presence of numerous scattered secondary lobular and lobar areas of decreased density and vascularity strongly suggests the diagnosis of chronic HP. This diagnosis is supported when associated with centrilobular nodules and patchy foci of ground-glass attenuation. Even in the presence of diffuse reticulation, secondary lobular air trapping should still suggest chronic HP (Figure 4). Pathologically, chronic HP is characterized by bronchocentric cellular interstitial pneumonia, poorly formed granulomas, and foci of organizing pneumonia (present in approximately two-thirds of cases, respectively) and interstitial fibrosis.

Distinguishing UIP and NSIP from chronic HP. It is now estimated that hypersensitivity pneumonitis represents between 15 and 20% of chronic lung disease as of 2001 (46). Unfortunately, despite growing awareness of the importance of hypersensitivity as a cause of diffuse lung disease, establishing the diagnosis frequently remains problematic (47). The diagnosis is often inferential, with no established "gold standard," and is based on an array of nonspecific clinical, radiologic, and, rarely, pathologic findings (48). These include but are not limited to a suggestive exposure history, serum-precipitating antibodies to suspected antigens, inhalational challenge, abnormal pulmonary function tests typically showing a restrictive pattern, and radiographic evidence of diffuse reticulation. Although specific circulating antibodies are evidence of prior exposure but not necessarily disease, as noted by Selman and colleagues, in the appropriate

clinical setting a positive test supports the diagnosis (47). More definitive evidence either requires demonstration of a lymphocytic alveolitis on bronchoalveolar lavage (BAL) or, less commonly, the finding of noncaseating peribronchial/interstitial granulomas on open lung biopsy (47, 48). In the absence of these criteria, UIP, NSIP, or organizing pneumonia may be the sole histopathologic findings, hence the need to maintain a high index of suspicion in any patient presenting with a clinical history of diffuse interstitial lung fibrosis (49, 50).

HRCT findings of hypersensitivity pneumonitis have been extensively reviewed (51–53). Although chronic HP typically presents with findings characteristic of both UIP and NSIP, in select cases distinct HRCT findings are often present that suggest the correct diagnosis.

As documented by Silva and colleagues in a retrospective study of 66 patients with proven chronic HP (n = 18) versus NSIP (n = 25) versus IPF (n = 23), HRCT features that best differentiated chronic HP from NSIP included: evidence of secondary lobular areas of decreased attenuation and vascularity, especially when present in five or more lobules in more than four lobes ($P < 0.001$); relative subpleural sparing ($P < 0.001$); extensive upper lobe involvement ($P < 0.001$), especially when peribronchovascular in distribution; and the presence of centrilobular nodules ($P < 0.001$) (3). In contrast, findings that best differentiated NSIP included relative subpleural sparing, absence of centrilobular ground-glass nodules, absence of honeycombing, and lack of air trapping ($P \leqslant 0.002$), whereas findings best distinguishing IPF included honeycombing without subpleural sparing or centrilobular nodules ($P \leqslant 0.004$). Based on these differential features, although a confident diagnosis was made in only 70 (53%) of 132 readings, of these the diagnosis proved correct in 66 (94%). Overall interobserver agreement was also notably good to excellent (k = 0.77–0.96). Interestingly, although secondary lobular air trapping was best defined on expiratory images, this did not significantly affect diagnostic accuracy in this study when compared with inspiratory images.

MANAGEMENT IMPLICATIONS OF HRCT

As important as the potential diagnostic implications of the various HRCT patterns described, there are clear management implications as well (Figure 5). In the setting of a definite UIP pattern, honeycombing is indicative of end-stage lung disease—regardless of the underlying etiology—for which surgical biopsy is no longer indicated. Establishing the presence of honeycombing, however, requires that CT studies be performed with meticulous technique and that a consistent definition of honeycombing be used. It cannot be overemphasized that cases in which the presence of honeycombing is considered equivocal should be considered to have a possible UIP pattern (15).

In contrast, for patients presenting with a possible UIP pattern, surgical lung biopsies should be strongly considered (44, 54, 55). There are number of valid reasons for obtaining surgical lung biopsies in these cases. IPF and NSIP (both cellular and fibrotic forms), in particular, have different survivals and outcomes, with IPF demonstrating an overall 5-year mortality of 50 to 70% (56) compared with idiopathic NSIP exhibiting a 20% 5-year mortality (38). Unfortunately, in the absence of honeycombing the diagnosis of IPF is frequently problematic. In one study of 55 biopsy-proven cases of IPF evaluated by at least two observers, 34 (32%) were considered to have atypical HRCT findings. Differential diagnoses in these cases interpreted with a high degree of confidence included NSIP in 18 (53%) and chronic HP in 4 (12%), among other diagnoses, whereas in 8 cases (23%), no single diagnosis was prioritized (44).

In addition to providing a more definitive diagnosis, surgical lung biopsy may play an important role in refining prognosis. Flaherty and colleagues found that in histologically confirmed UIP, 26% also had NSIP in a second or third lobe, leading investigators to propose a histopathologic classification based on four distinct patterns in patients with idiopathic interstitial pneumonias to reflect prognosis: concordant UIP, with UIP pattern in all lobes; discordant UIP, with a UIP pattern in at least one lobe but a non-UIP pattern in at least one other lobe; concordant fibrotic NSIP seen in at least one lobe; and concordant cellular NSIP, present in all lobes (57). Significant correlations could be established between these various patterns and prognosis, with the worst outcomes occurring in patients with concordant UIP. The best outcomes occurred in patients with concordant NSIP. Nearly identical findings have also been reported by Monaghan and colleagues (58). In this study of 64 patients evaluated for possible IPF in whom multiple biopsies were obtained, discordant UIP-NSIP was identified in 12.5% compared with 39.1% of patients with concordant UIP-UIP and 48.4% with

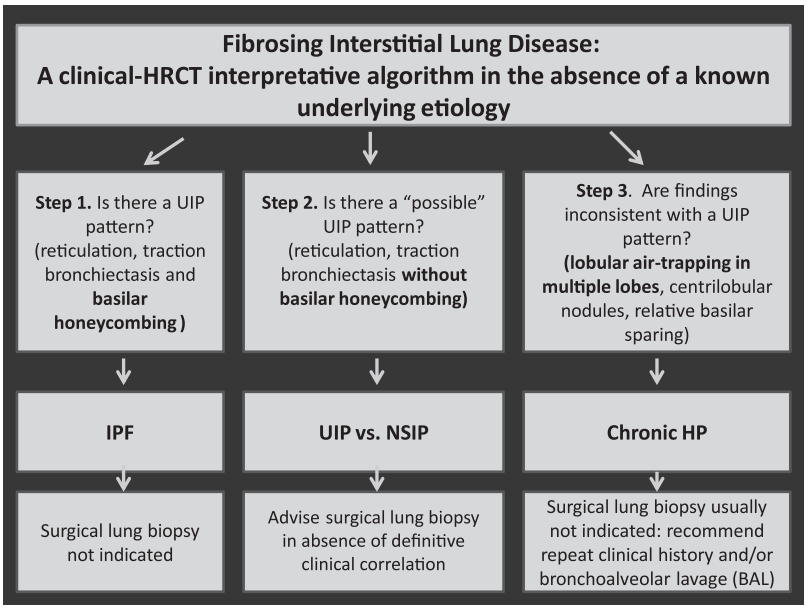

Figure 5. Fibrosing interstitial lung disease: a clinical–high-resolution computed tomography interpretive algorithm in the absence of a known underlying etiology. HP = hypersensitivity pneumonitis; IPF = idiopathic pulmonary fibrosis; NSIP = nonspecific interstitial pneumonitis; UIP = usual interstitial pneumonia.

concordant NSIP-NSIP. Similar to the findings of Flaherty and colleagues (57), the discordant group had a prognosis closer to concordant UIP than NISP.

A further argument proposed for establishing a specific histologic diagnosis is the fact that approximately 15 to 20% of patients initially presenting with interstitial lung disease in the absence of definitive clinical signs, including a possible UIP pattern, ultimately develop a CTD (59, 60). As reported by Fischer and colleagues, in addition to diagnosing NSIP, histologic findings that are strongly suggestive of an underlying CTD include dense perivascular collagen, extensive pleuritis, lymphoid aggregates with germinal center formation, and prominent plasmacytic infiltration (59). In conjunction with extensive serologic testing, it is proposed that these findings when present constitute a distinct phenotype—lung-dominant CTD.

Further evidence for the potential value of histologic evaluation in patients with suspected underlying CTD has been published by Vij and colleagues (61). In their study of 200 patients with HRCT and histologic evidence of interstitial lung disease, 63 (32%) were identified in whom there were either signs, symptoms, and/or serologic test results consistent with an underlying autoimmune disease without meeting strict rheumatologic criteria for establishing a diagnosis of a CTD. Of these 63 patients, 62% had HRCT findings typical of UIP, whereas 21 (33%) had atypical HRCT findings. Of 17 patients with HRCT pattern of typical UIP undergoing biopsy, all had histologic evidence of UIP. Of 12 patients with atypical HRCT findings undergoing biopsy, 6 had UIP, 2 had NSIP, and 4 were considered unclassifiable. This has recently led these investigators to propose a new classification—autoimmune-featured interstitial lung disease (62).

Establishing the etiology of FILD is also important, particularly when enrolling patients in prospective novel treatment trials (63–67).

Based on these and similar findings, an approach emphasizing a critical role for HRCT has been proposed by Travis and colleagues emphasizing the need for final diagnoses to reflect concordance or a lack thereof between histopathologic and HRCT findings (38)

It should be emphasized that a decision to obtain a surgical lung biopsy requires careful evaluation of potential risks. Although the actual risk of a surgical lung biopsy is a matter of dispute, with some reporting perioperative mortality rates as high as 7.6% (68, 69), most reports have concluded that in properly selected cases, surgical lung biopsy should be considered a relatively safe procedure (32, 55, 70, 71). Conditions that lead to higher risks of surgical lung biopsy include: older age (55), immunocompromised states or the need for mechanical ventilation at the time of surgery (70, 71), or attempted surgery for coexistent lung neoplasia (71). As documented by Lettieri and colleagues, in a retrospective study of 83 patients with diffuse ILD, the overall mortality rate at 90 days was only 1.5% in patients with clinically stable IPF (70). Similar results have been reported by others. In one prospective study of 91 clinically stable patients with diffuse lung disease biopsies, death due to surgical complications occurred in a single case only (32). In evaluating potential candidates for surgical lung biopsy, it is also worth emphasizing that there is a well-documented risk to the empiric use of steroid therapy in general, as well as in patients with IPF.

Finally, when HRCT findings are inconsistent with a UIP pattern, alternate diagnostic means than surgical lung biopsy should be considered. Patients presenting with findings consistent with chronic HP, in particular, represent an important subset for which a nonsurgical approach is clearly preferable. Although controversial in this setting, BAL has been reported to play a critical role in differentiating chronic HP from UIP/IPF (72). In conjunction with a suggestive exposure history and serum-precipitating antibodies, BAL characteristically shows a lymphocytic alveolitis (>40%), a finding distinctly unusual with UIP/IPF (73). In contrast, the role of transbronchial biopsy is less established, as it is unusual to detect nonnecrotizing granulomas due to limited tissue sampling, and even when present they are nonspecific.

CONCLUSIONS

It is now accepted as axiomatic that accurate diagnosis of diffuse lung disease involves a "dynamic integrated approach" using clinical-radiologic-pathologic correlation (2). In fact, however, HRCT studies are frequently acquired with only the vaguest clinical histories and incomplete laboratory correlation. Although this may in part reflect a tendency to overreliance on imaging technology, it is also apparent that many cases remain problematic even when detailed clinical histories and physical findings are assessed. In the specific context of FILD, there is an apparent need in particular to develop a diagnostic strategy based on initial HRCT findings. For this purpose, the American Thoracic Society/European Respiratory Society/Japanese Respiratory Society/Latin American Thoracic Association HRCT guidelines proposed to specifically diagnosis IPF are easily expanded to suggest guidelines for the diagnosis of patients with diffuse lung fibrosis in the absence of a known underlying etiology. The development of an algorithmic approach based on an HRCT classification is facilitated by the fact that in the vast majority of these cases, the most frequent clinical diagnoses are either IPF/UIP, NSIP, or chronic HP. In our opinion, the latter diagnosis has been insufficiently emphasized in the context of differentiating UIP from NSIP. In addition to suggesting a correct diagnosis, this approach serves equally well as a guide to subsequent management. Most importantly, this includes an emphasis on obtaining surgical lung biopsies in patients presenting with a possible UIP pattern. In fact, it is likely that surgical lung biopsies are too infrequently obtained in this setting for fear of potentially misleading sampling errors (74), significant interobserver variability, and potential complications. Surgical lung biopsies also are of limited value for following the course of disease (75). Acknowledging the need for careful selection, it is specifically in cases with a possible UIP pattern that surgical lung biopsy should most often be considered. Not only do surgical biopsies enhance diagnostic certainty, including in select cases the potential of an early diagnosis of previously undetected CTD, they have important prognostic implications. Finally, by suggesting the diagnosis of chronic HP, HRCT may play an equally critical role by suggesting BAL in place of surgical lung biopsy.

It is anticipated that although practicable use of an algorithm based on distinct HRCT patterns in patients with FILD will prove of value, final acceptance must await further clinical validation, for which prospective clinical evaluation would be warranted.

Author disclosures are available with the text of this article at www.atsjournals.org.

References

1. Alhamad EH, Cosgrove GP. Interstitial lung disease: the initial approach. *Med Clin North Am* 2011;95:1071–1093.
2. American Thoracic Society/European Respiratory Society International Multidisciplinary Consensus Classification of the Idiopathic Interstitial Pneumonias. This joint statement of the American Thoracic Society (ATS), and the European Respiratory Society (ERS) was adopted by the ATS board of directors, June 2001 and by the ERS Executive Committee, 2001. *Am J Respir Crit Care Med* 2002;165:277–304.
3. Silva CI, Müller NL, Lynch DA, Curran-Everett D, Brown KK, Lee KS, Chung MP, Churg A. Chronic hypersensitivity pneumonitis: differentiation

from idiopathic pulmonary fibrosis and nonspecific interstitial pneumonia by using thin-section CT. *Radiology* 2008;246:288–297.
4. Churg A, Müller NL. Cellular vs fibrosing interstitial pneumonias and prognosis: a practical classification of the idiopathic interstitial pneumonias and pathologically/radiologically similar conditions. *Chest* 2006;130:1566–1570.
5. Raghu G, Collard HR, Egan JJ, Martinez FJ, Behr J, Brown KK, Colby TV, Cordier JF, Flaherty KR, Lasky JA, *et al*.; ATS/ERS/JRS/ALAT Committee on Idiopathic Pulmonary Fibrosis. An official ATS/ERS/JRS/ALAT statement: idiopathic pulmonary fibrosis: evidence-based guidelines for diagnosis and management. *Am J Respir Crit Care Med* 2011;183:788–824.
6. Lucidarme O, Grenier P, Coche E, Lenoir S, Aubert B, Beigelman C. Bronchiectasis: comparative assessment with thin-section CT and helical CT. *Radiology* 1996;200:673–679.
7. Tarver RD, Conces DJ Jr, Godwin JD. Motion artifacts on CT simulate bronchiectasis. *AJR Am J Roentgenol* 1988;151:1117–1119.
8. Christe A, Charimo-Torrente J, Roychoudhury K, Vock P, Roos JE. Accuracy of low-dose computed tomography (CT) for detecting and characterizing the most common CT-patterns of pulmonary disease. *Eur J Radiol* 2013;82:e142–e150.
9. Raman SP, Johnson PT, Deshmukh S, Mahesh M, Grant KL, Fishman EK. CT dose reduction applications: available tools on the latest generation of CT scanners. *J Am Coll Radiol* 2013;10:37–41.
10. Dodd JD, de Jong PA, Levy RD, Coxson HO, Mayo JR. Conventional high-resolution CT versus contiguous multidetector CT in the detection of bronchiolitis obliterans syndrome in lung transplant recipients. *J Thorac Imaging* 2008;23:235–243.
11. Aldrich JE, Bilawich AM, Mayo JR. Radiation doses to patients receiving computed tomography examinations in British Columbia. *Can Assoc Radiol J* 2006;57:79–85.
12. Hansell DM, Bankier AA, MacMahon H, McLoud TC, Müller NL, Remy J. Fleischner Society: glossary of terms for thoracic imaging. *Radiology* 2008;246:697–722.
13. Flaherty KR, Andrei AC, King TE Jr, Raghu G, Colby TV, Wells A, Bassily N, Brown K, du Bois R, Flint A, *et al*. Idiopathic interstitial pneumonia: do community and academic physicians agree on diagnosis? *Am J Respir Crit Care Med* 2007;175:1054–1060.
14. Lynch DA, Godwin JD, Safrin S, Starko KM, Hormel P, Brown KK, Raghu G, King TE Jr, Bradford WZ, SchwartZ DA, *et al*. High-resolution computed tomography in idiopathic pulmonary fibrosis: diagnosis and prognosis. *Am J Respir Crit Care Med* 2005;172:488–493.
15. Watadani T, Sakai F, Johkoh T, Noma S, Akira M, Fujimoto K, Bankier AA, Lee KS, Müller NL, Song JW, *et al*. Interobserver variability in the CT assessment of honeycombing in the lungs. *Radiology* 2013;266:936–944.
16. Arakawa H, Honma K. Honeycomb lung: history and current concepts. *AJR Am J Roentgenol* 2011;196:773–782.
17. Katzenstein A-LA. Idiopathic interstitial pneumonia. In: Katzenstein and Askin's surgical pathology of non-neoplastic lung disease. Philadelphia, PA: Saunders; 2006. pp. 51–84.
18. du Bois RM. An earlier and more confident diagnosis of idiopathic pulmonary fibrosis. *Eur Respir Rev* 2012;21:141–146.
19. Kim DS, Park JH, Park BK, Lee JS, Nicholson AG, Colby T. Acute exacerbation of idiopathic pulmonary fibrosis: frequency and clinical features. *Eur Respir J* 2006;27:143–150.
20. Ambrosini V, Cancellieri A, Chilosi M, Zompatori M, Trisolini R, Saragoni L, Poletti V. Acute exacerbation of idiopathic pulmonary fibrosis: report of a series. *Eur Respir J* 2003;22:821–826.
21. Akira M, Sakatani M, Ueda E. Idiopathic pulmonary fibrosis: progression of honeycombing at thin-section CT. *Radiology* 1993;189:687–691.
22. Taskar VS, Coultas DB. Is idiopathic pulmonary fibrosis an environmental disease? *Proc Am Thorac Soc* 2006;3:293–298.
23. al-Jarad N, Strickland B, Pearson MC, Rubens MB, Rudd RM. High resolution computed tomographic assessment of asbestosis and cryptogenic fibrosing alveolitis: a comparative study. *Thorax* 1992;47:645–650.
24. Corrin B, Dewar A, Rodriguez-Roisin R, Turner-Warwick M. Fine structural changes in cryptogenic fibrosing alveolitis and asbestosis. *J Pathol* 1985;147:107–119.
25. Thannickal VJ. Idiopathic interstitial pneumonia: a clinicopathological perspective. *Semin Respir Crit Care Med* 2006;27:569–573.
26. Mueller-Mang C, Grosse C, Schmid K, Stiebellehner L, Bankier AA. What every radiologist should know about idiopathic interstitial pneumonias. *Radiographics* 2007;27:595–615.
27. Nishimura K, Kitaichi M, Izumi T, Nagai S, Kanaoka M, Itoh H. Usual interstitial pneumonia: histologic correlation with high-resolution CT. *Radiology* 1992;182:337–342.
28. Sumikawa H, Johkoh T, Ichikado K, Taniguchi H, Kondoh Y, Fujimoto K, Tateishi U, Hiramatsu T, Inoue A, Natsag J, *et al*. Usual interstitial pneumonia and chronic idiopathic interstitial pneumonia: analysis of CT appearance in 92 patients. *Radiology* 2006;241:258–266.
29. Grenier P, Valeyre D, Cluzel P, Brauner MW, Lenoir S, Chastang C. Chronic diffuse interstitial lung disease: diagnostic value of chest radiography and high-resolution CT. *Radiology* 1991;179:123–132.
30. Tung KT, Wells AU, Rubens MB, Kirk JM, du Bois RM, Hansell DM. Accuracy of the typical computed tomographic appearances of fibrosing alveolitis. *Thorax* 1993;48:334–338.
31. Swensen SJ, Aughenbaugh GL, Myers JL. Diffuse lung disease: diagnostic accuracy of CT in patients undergoing surgical biopsy of the lung. *Radiology* 1997;205:229–234.
32. Hunninghake GW, Zimmerman MB, Schwartz DA, King TE Jr, Lynch J, Hegele R, Waldron J, Colby T, Müller N, Lynch D, *et al*. Utility of a lung biopsy for the diagnosis of idiopathic pulmonary fibrosis. *Am J Respir Crit Care Med* 2001;164:193–196.
33. Aziz ZA, Wells AU, Hansell DM, Bain GA, Copley SJ, Desai SR, Ellis SM, Gleeson FV, Grubnic S, Nicholson AG, *et al*. HRCT diagnosis of diffuse parenchymal lung disease: inter-observer variation. *Thorax* 2004;59:506–511.
34. Lynch DA. High-resolution CT of idiopathic interstitial pneumonias. *Radiol Clin North Am* 2001;39:1153–1170.
35. Flaherty KR, Thwaite EL, Kazerooni EA, Gross BH, Toews GB, Colby TV, Travis WD, Mumford JA, Murray S, Flint A, *et al*. Radiological versus histological diagnosis in UIP and NSIP: survival implications. *Thorax* 2003;58:143–148.
36. Kim EY, Lee KS, Chung MP, Kwon OJ, Kim TS, Hwang JH. Nonspecific interstitial pneumonia with fibrosis: serial high-resolution CT findings with functional correlation. *AJR Am J Roentgenol* 1999;173:949–953.
37. Johkoh T, Müller NL, Colby TV, Ichikado K, Taniguchi H, Kondoh Y, Fujimoto K, Kinoshita M, Arakawa H, Yamada H, *et al*. Nonspecific interstitial pneumonia: correlation between thin-section CT findings and pathologic subgroups in 55 patients. *Radiology* 2002;225:199–204.
38. Travis WD, Hunninghake G, King TE Jr, Lynch DA, Colby TV, Galvin JR, Brown KK, Chung MP, Cordier JF, du Bois RM, *et al*. Idiopathic nonspecific interstitial pneumonia: report of an American Thoracic Society project. *Am J Respir Crit Care Med* 2008;177:1338–1347.
39. Tsubamoto M, Müller NL, Johkoh T, Ichikado K, Taniguchi H, Kondoh Y, Fujimoto K, Arakawa H, Koyama M, Kozuka T, *et al*. Pathologic subgroups of nonspecific interstitial pneumonia: differential diagnosis from other idiopathic interstitial pneumonias on high-resolution computed tomography. *J Comput Assist Tomogr* 2005;29:793–800.
40. MacDonald SL, Rubens MB, Hansell DM, Copley SJ, Desai SR, du Bois RM, Nicholson AG, Colby TV, Wells AU. Nonspecific interstitial pneumonia and usual interstitial pneumonia: comparative appearances at and diagnostic accuracy of thin-section CT. *Radiology* 2001;221:600–605.
41. Wells AU, Hansell DM, Rubens MB, Cullinan P, Black CM, du Bois RM. The predictive value of appearances on thin-section computed tomography in fibrosing alveolitis. *Am Rev Respir Dis* 1993;148:1076–1082.
42. Desai SR, Veeraraghavan S, Hansell DM, Nikolakopolou A, Goh NS, Nicholson AG, Colby TV, Denton CP, Black CM, du Bois RM, *et al*. CT features of lung disease in patients with systemic sclerosis: comparison with idiopathic pulmonary fibrosis and nonspecific interstitial pneumonia. *Radiology* 2004;232:560–567.
43. Kim MY, Song JW, Do KH, Jang SJ, Colby TV, Kim DS. Idiopathic nonspecific interstitial pneumonia: changes in high-resolution computed tomography on long-term follow-up. *J Comput Assist Tomogr* 2012;36:170–174.
44. Sverzellati N, Wells AU, Tomassetti S, Desai SR, Copley SJ, Aziz ZA, Zompatori M, Chilosi M, Nicholson AG, Poletti V, *et al*. Biopsy-proved idiopathic pulmonary fibrosis: spectrum of nondiagnostic thin-section CT diagnoses. *Radiology* 2010;254:957–964.

45. Akira M, Inoue Y, Kitaichi M, Yamamoto S, Arai T, Toyokawa K. Usual interstitial pneumonia and nonspecific interstitial pneumonia with and without concurrent emphysema: thin-section CT findings. *Radiology* 2009;251:271–279.
46. Thomeer MJ, Costabe U, Rizzato G, Poletti V, Demedts M. Comparison of registries of interstitial lung diseases in three European countries. *Eur Respir J Suppl* 2001;32:114s–118s.
47. Selman M, Pardo A, King TE Jr. Hypersensitivity pneumonitis: insights in diagnosis and pathobiology. *Am J Respir Crit Care Med* 2012;186: 314–324.
48. Schuyler M, Cormier Y. The diagnosis of hypersensitivity pneumonitis. *Chest* 1997;111:534–536.
49. Lacasse Y, Girard M, Cormier Y. Recent advances in hypersensitivity pneumonitis. *Chest* 2012;142:208–217.
50. Vourlekis JS, Schwarz MI, Cool CD, Tuder RM, King TE, Brown KK. Nonspecific interstitial pneumonitis as the sole histologic expression of hypersensitivity pneumonitis. *Am J Med* 2002;112:490–493.
51. Lacasse Y, Selman M, Costabel U, Dalphin JC, Ando M, Morell F, Erkinjuntti-Pekkanen R, Muller N, Colby TV, Schuyler M, *et al.*; HP Study Group. Clinical diagnosis of hypersensitivity pneumonitis. *Am J Respir Crit Care Med* 2003;168:952–958.
52. Silva CI, Müller NL, Hansell DM, Lee KS, Nicholson AG, Wells AU. Nonspecific interstitial pneumonia and idiopathic pulmonary fibrosis: changes in pattern and distribution of disease over time. *Radiology* 2008;247:251–259.
53. Silva CIS, Churg A, Müller NL. Hypersensitivity pneumonitis: spectrum of high-resolution CT and pathologic findings. *AJR Am J Roentgenol* 2007;188:334–344.
54. Travis WD, Matsui K, Moss J, Ferrans VJ. Idiopathic nonspecific interstitial pneumonia: prognostic significance of cellular and fibrosing patterns: survival comparison with usual interstitial pneumonia and desquamative interstitial pneumonia. *Am J Surg Pathol* 2000;24:19–33.
55. Fell CD, Martinez FJ, Liu LX, Murray S, Han MK, Kazerooni EA, Gross BH, Myers J, Travis WD, Colby TV, *et al.* Clinical predictors of a diagnosis of idiopathic pulmonary fibrosis. *Am J Respir Crit Care Med* 2010;181:832–837.
56. du Bois R, King TE Jr. Challenges in pulmonary fibrosis x 5: the NSIP/UIP debate. *Thorax* 2007;62:1008–1012.
57. Flaherty KR, Travis WD, Colby TV, Toews GB, Kazerooni EA, Gross BH, Jain A, Strawderman RL, Flint A, Lynch JP, *et al.* Histopathologic variability in usual and nonspecific interstitial pneumonias. *Am J Respir Crit Care Med* 2001;164:1722–1727.
58. Monaghan H, Wells AU, Colby TV, du Bois RM, Hansell DM, Nicholson AG. Prognostic implications of histologic patterns in multiple surgical lung biopsies from patients with idiopathic interstitial pneumonias. *Chest* 2004; 125:522–526.
59. Fischer A, West SG, Swigris JJ, Brown KK, du Bois RM. Connective tissue disease-associated interstitial lung disease: a call for clarification. *Chest* 2010;138:251–256.
60. Kinder BW, Collard HR, Koth L, Daikh DI, Wolters PJ, Elicker B, Jones KD, King TE Jr. Idiopathic nonspecific interstitial pneumonia: lung manifestation of undifferentiated connective tissue disease? *Am J Respir Crit Care Med* 2007;176:691–697.
61. Vij R, Noth I, Strek ME. Autoimmune-featured interstitial lung disease: a distinct entity. *Chest* 2011;140:1292–1299.
62. Vij R, Strek ME. Diagnosis and treatment of connective tissue disease-associated interstitial lung disease. *Chest* 2013;143:814–824.
63. King TE Jr, Tooze JA, Schwarz MI, Brown KR, Cherniack RM. Predicting survival in idiopathic pulmonary fibrosis: scoring system and survival model. *Am J Respir Crit Care Med* 2001;164:1171–1181.
64. King TE Jr, Schwarz MI, Brown K, Tooze JA, Colby TV, Waldron JA Jr, Flint A, Thurlbeck W, Cherniack RM. Idiopathic pulmonary fibrosis: relationship between histopathologic features and mortality. *Am J Respir Crit Care Med* 2001;164:1025–1032.
65. Lama VN, Flaherty KR, Toews GB, Colby TV, Travis WD, Long Q, Murray S, Kazerooni EA, Gross BH, Lynch JP III, *et al.* Prognostic value of desaturation during a 6-minute walk test in idiopathic interstitial pneumonia. *Am J Respir Crit Care Med* 2003;168:1084–1090.
66. Bjoraker JA, Ryu JH, Edwin MK, Myers JL, Tazelaar HD, Schroeder DR, Offord KP. Prognostic significance of histopathologic subsets in idiopathic pulmonary fibrosis. *Am J Respir Crit Care Med* 1998;157: 199–203.
67. Katzenstein AL, Fiorelli RF. Nonspecific interstitial pneumonia/fibrosis. Histologic features and clinical significance. *Am J Surg Pathol* 1994; 18:136–147.
68. Mouroux J, Clary-Meinesz C, Padovani B, Perrin C, Rotomondo C, Chavaillon JM, Blaive B, Richelme H. Efficacy and safety of videothoracoscopic lung biopsy in the diagnosis of interstitial lung disease. *Eur J Cardiothorac Surg* 1997;11:22–24, 25–26.
69. Utz JP, Ryu JH, Douglas WW, Hartman TE, Tazelaar HD, Myers JL, Allen MS, Schroeder DR. High short-term mortality following lung biopsy for usual interstitial pneumonia. *Eur Respir J* 2001;17:175–179.
70. Lettieri CJ, Veerappan GR, Helman DL, Mulligan CR, Shorr AF. Outcomes and safety of surgical lung biopsy for interstitial lung disease. *Chest* 2005;127:1600–1605.
71. Sakamoto S, Homma S, Mun M, Fujii T, Kurosaki A, Yoshimura K. Acute exacerbation of idiopathic interstitial pneumonia following lung surgery in 3 of 68 consecutive patients: a retrospective study. *Intern Med* 2011;50:77–85.
72. Raghu G. Idiopathic pulmonary fibrosis: guidelines for diagnosis and clinical management have advanced from consensus-based in 2000 to evidence-based in 2011. *Eur Respir J* 2011;37:743–746.
73. Nagai S, Handa T, Ito Y, Takeuchi M, Izumi T. Bronchoalveolar lavage in idiopathic interstitial lung diseases. *Semin Respir Crit Care Med* 2007;28:496–503.
74. Johnston ID, Prescott RJ, Chalmers JC, Rudd RM; Fibrosing Alveolitis Subcommittee of the Research Committee of the British Thoracic Society. British Thoracic Society study of cryptogenic fibrosing alveolitis: current presentation and initial management. *Thorax* 1997;52:38–44.
75. Nicholson AG, Addis BJ, Bharucha H, Clelland CA, Corrin B, Gibbs AR, Hasleton PS, Kerr KM, Ibrahim NB, Stewart S, *et al.* Inter-observer variation between pathologists in diffuse parenchymal lung disease. *Thorax* 2004;59:500–505.